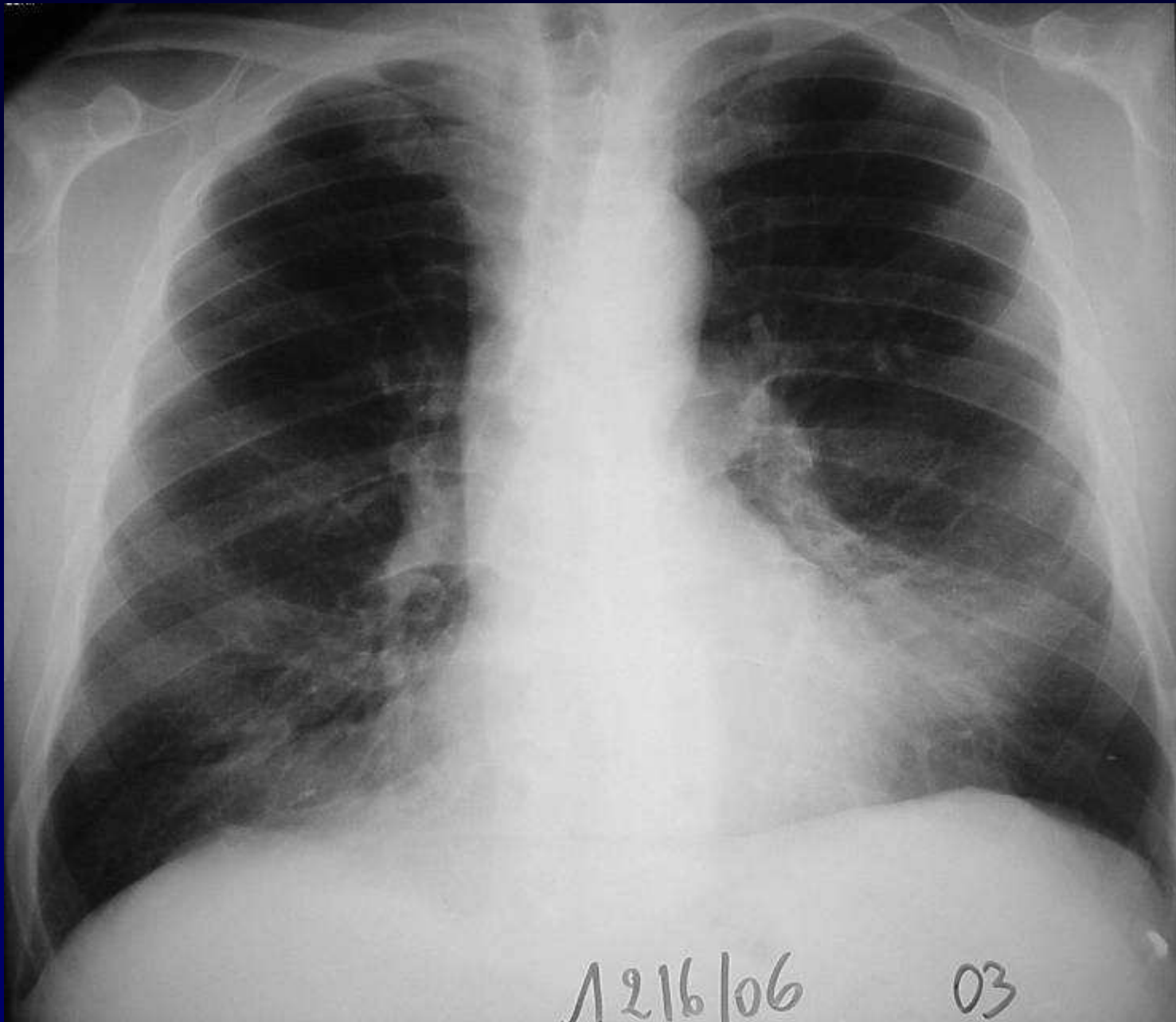
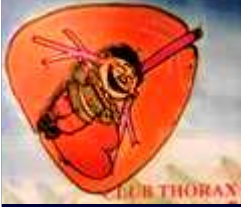

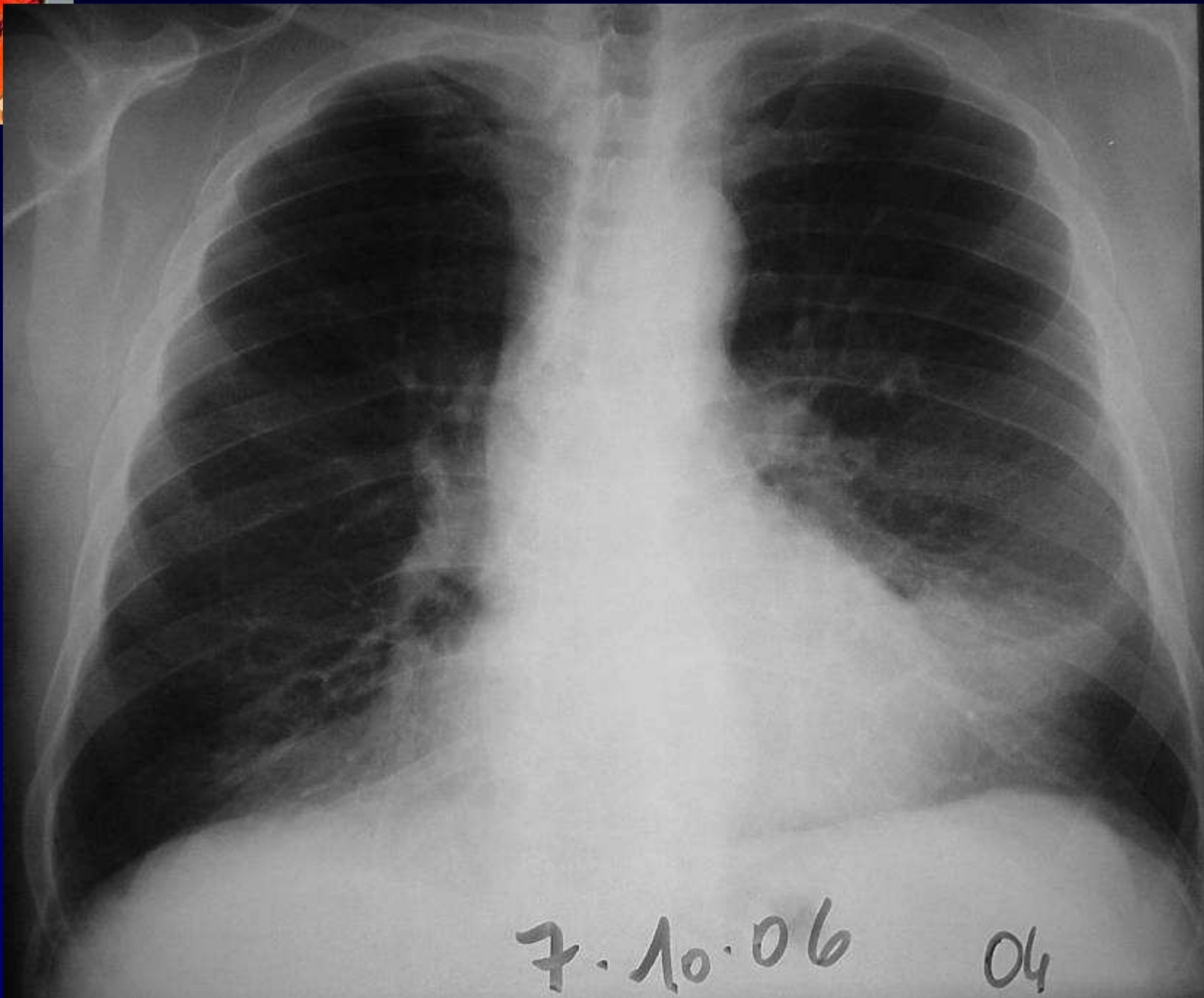

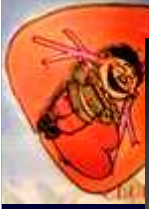
Dossier 10

**A Khalil
MF Carette**

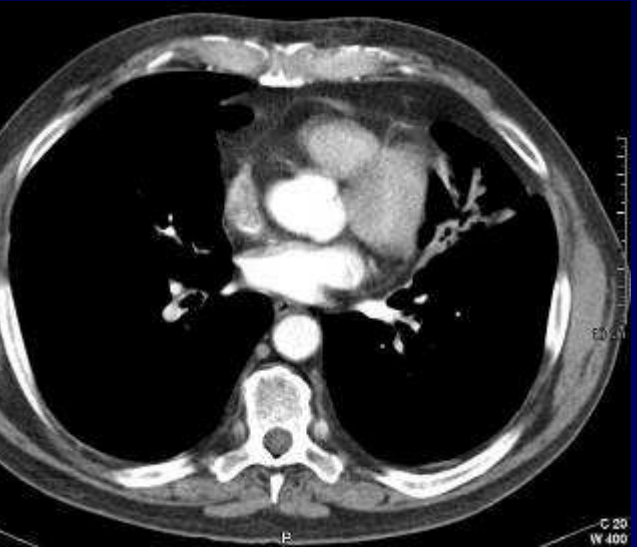
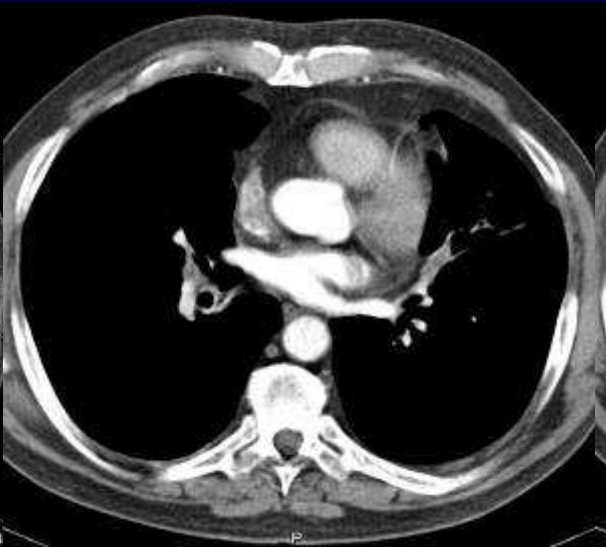
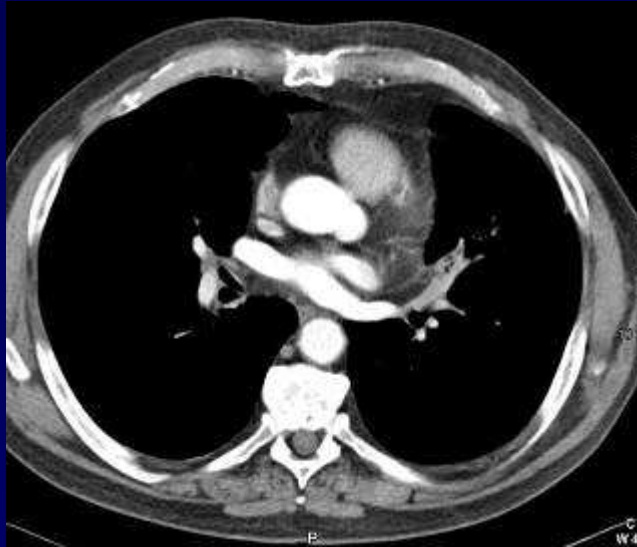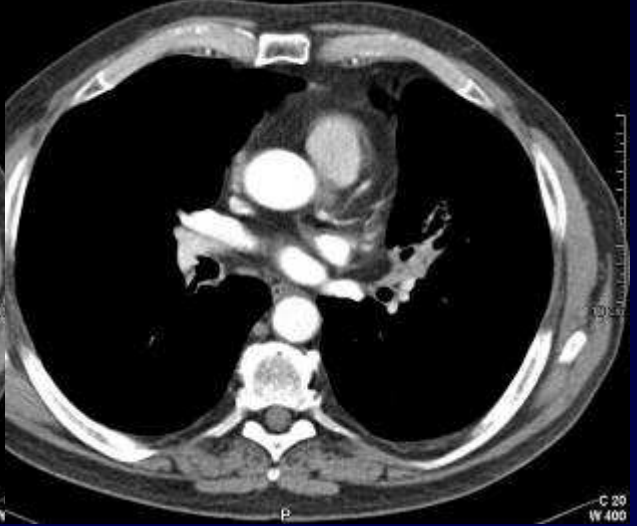
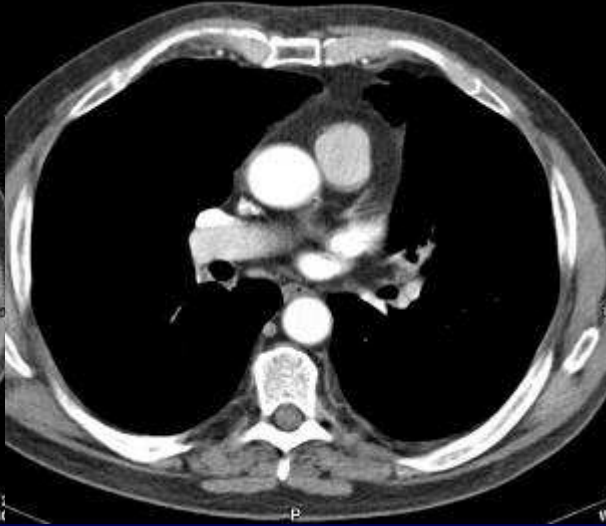
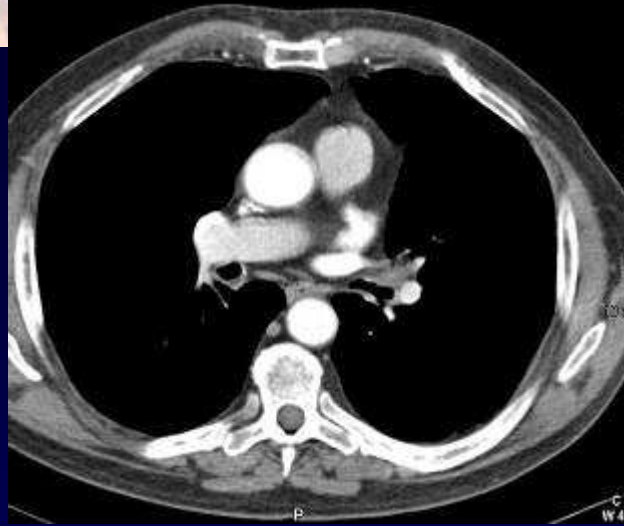
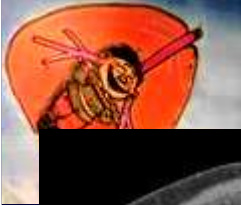**Femme de 67 ans
Infections pulmonaires à répétition
Intoxication tabagique: 38 PA**

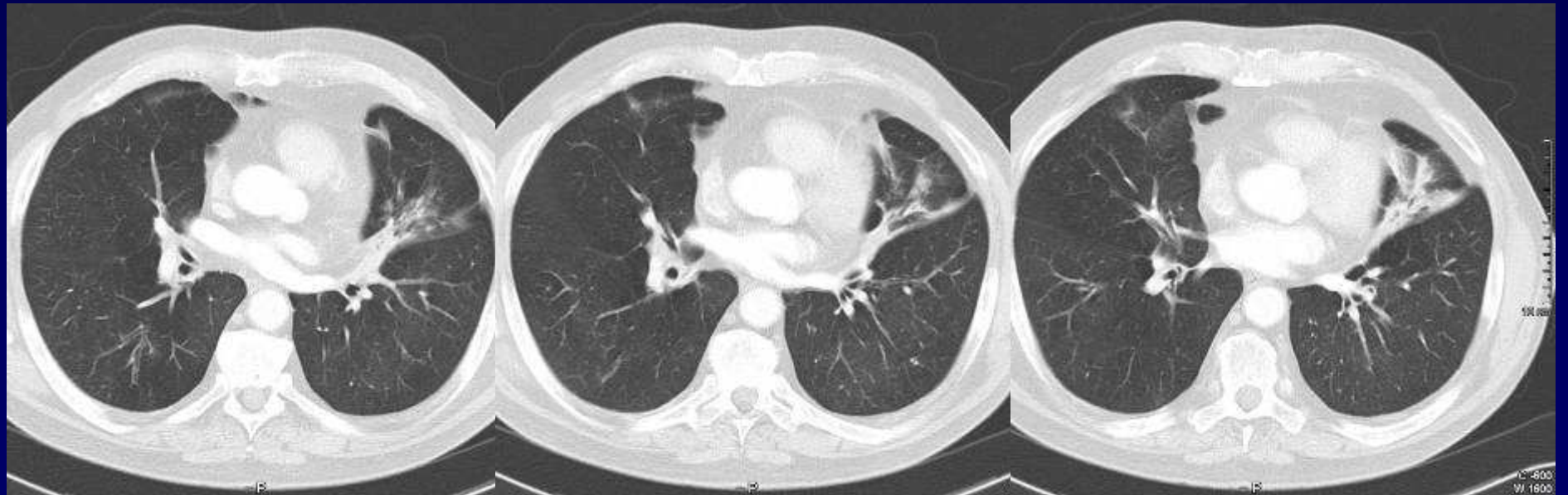
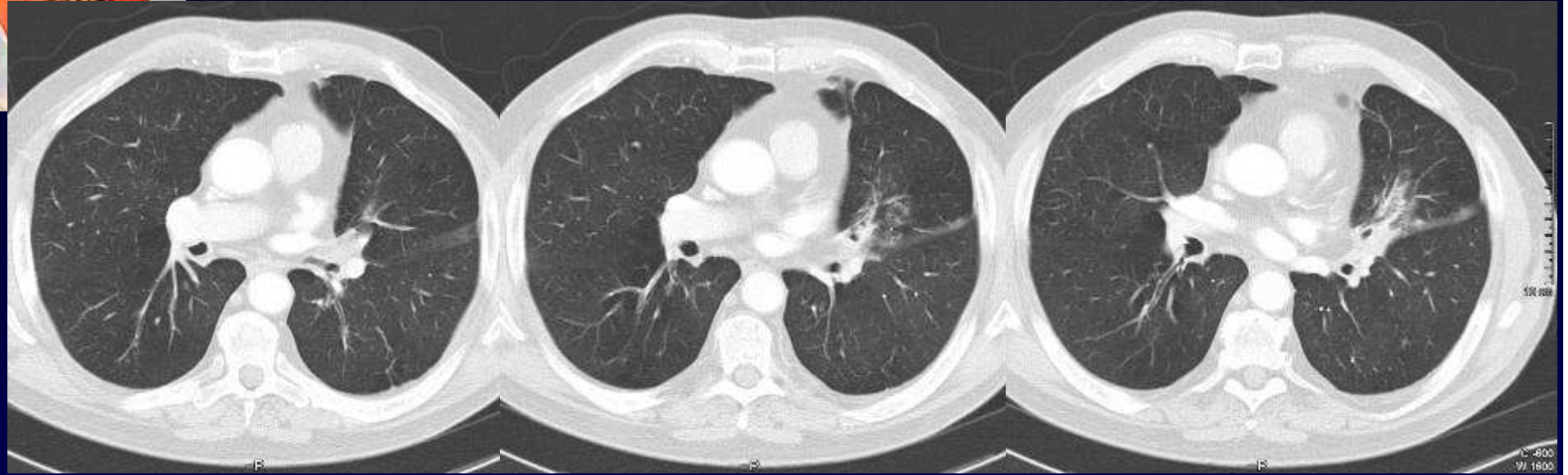
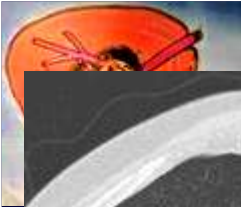

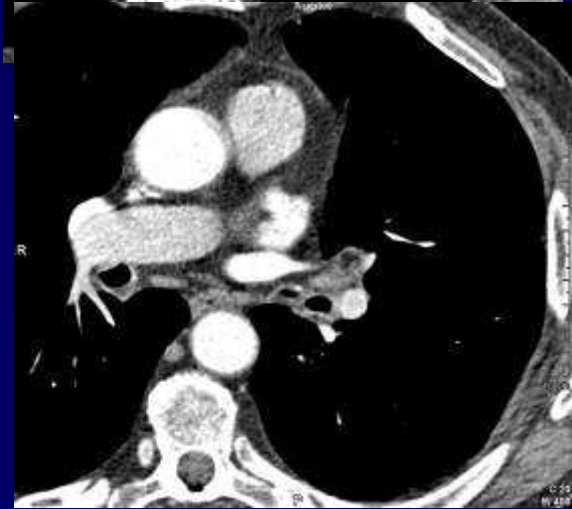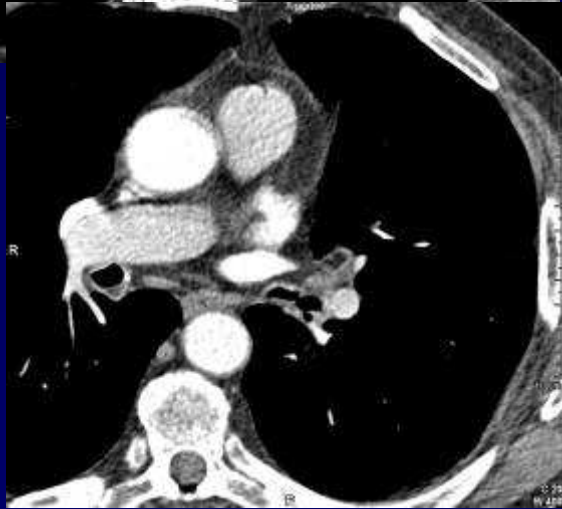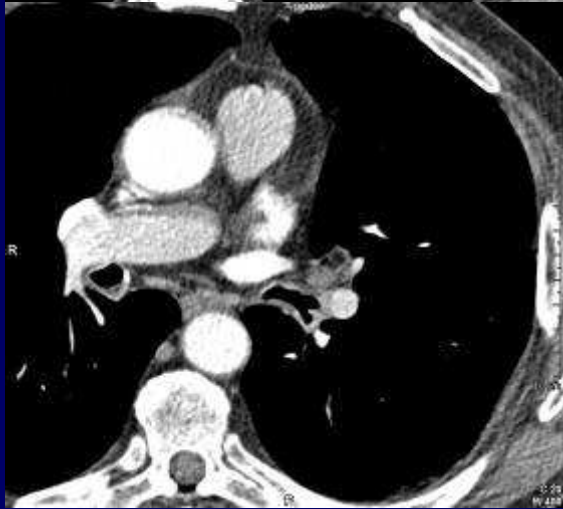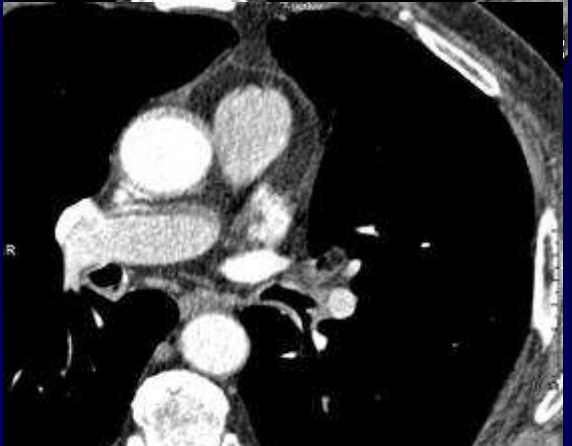
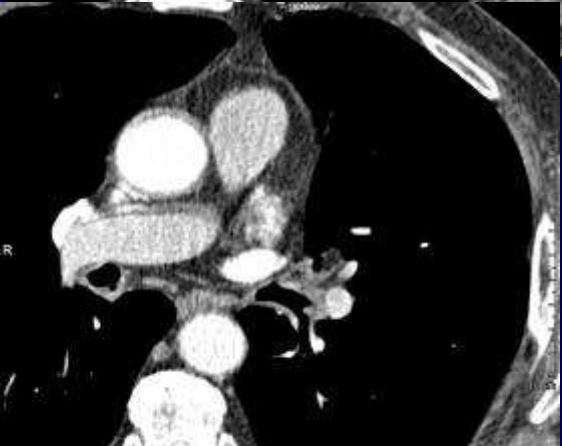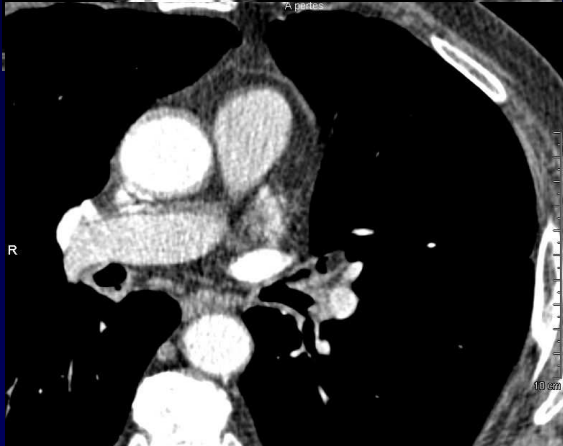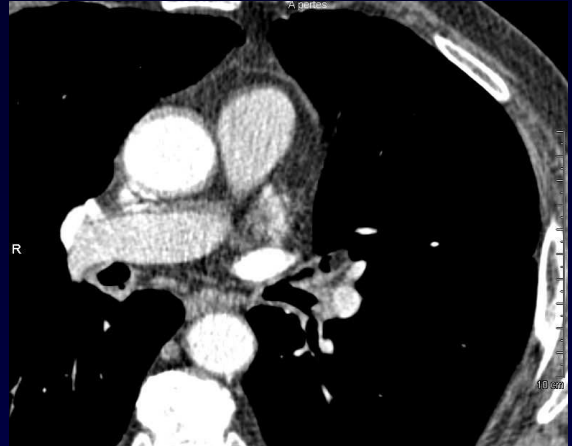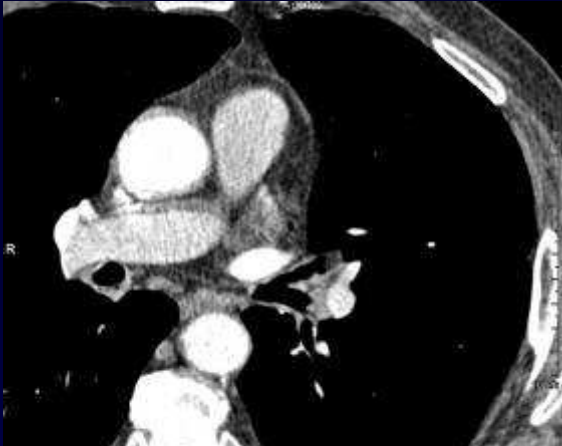
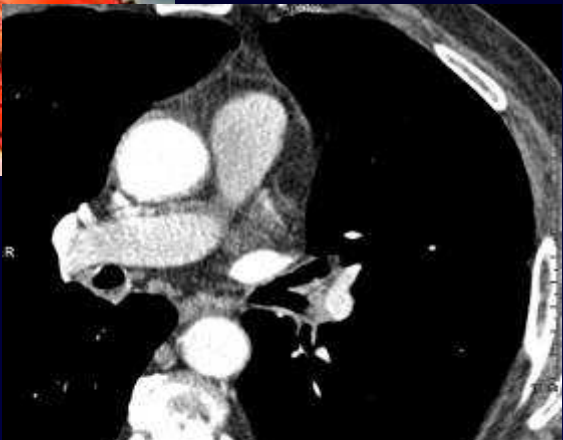


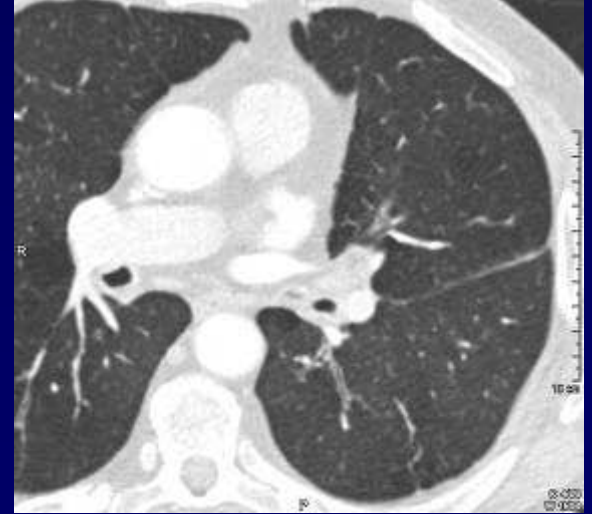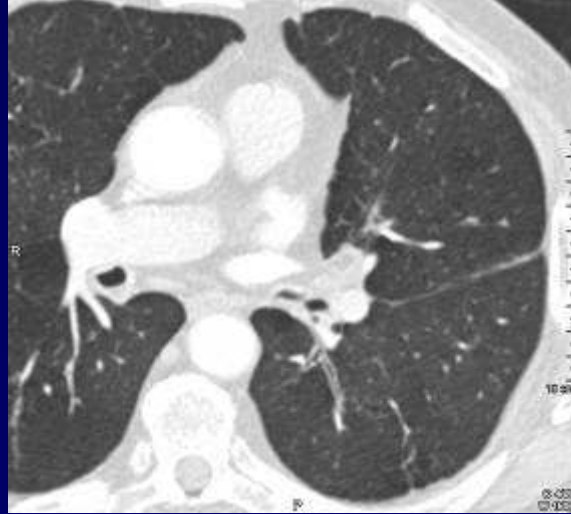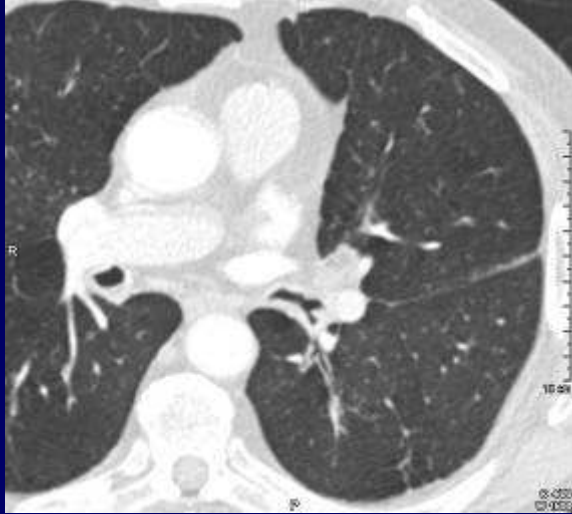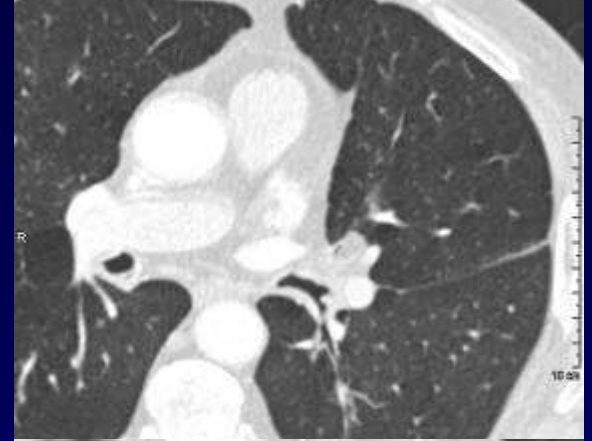
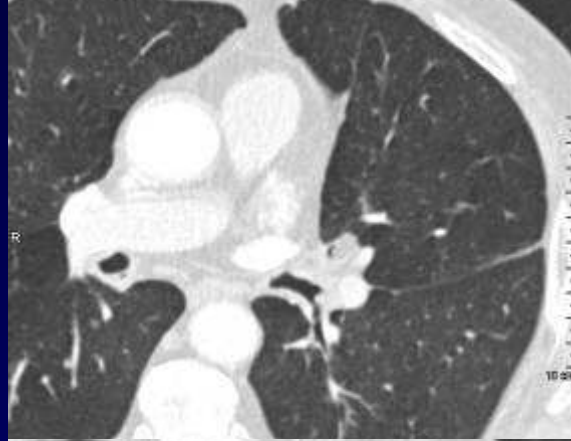
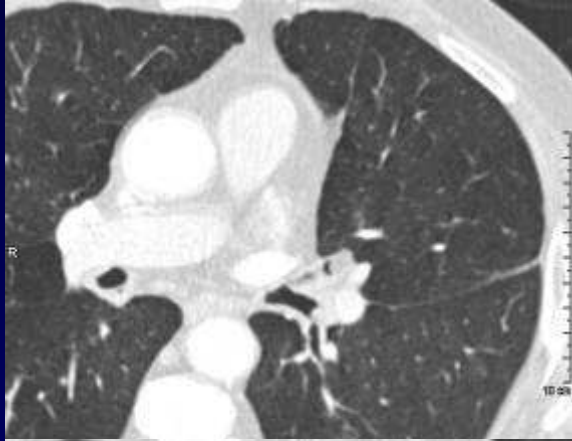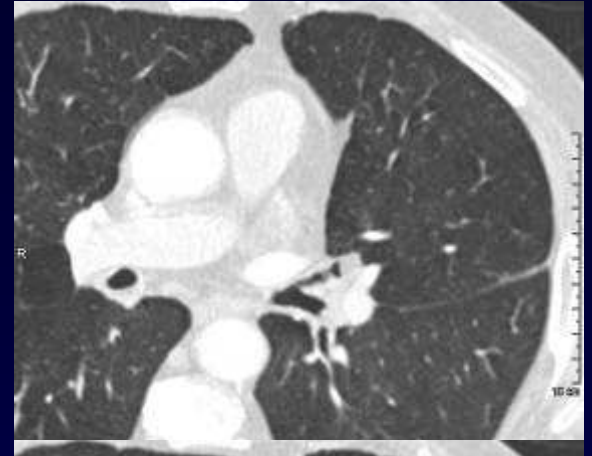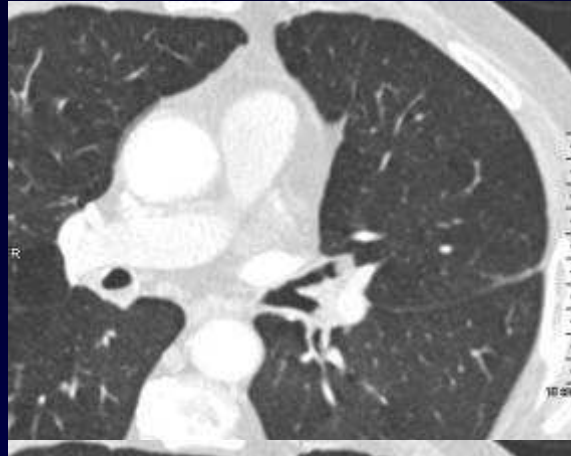
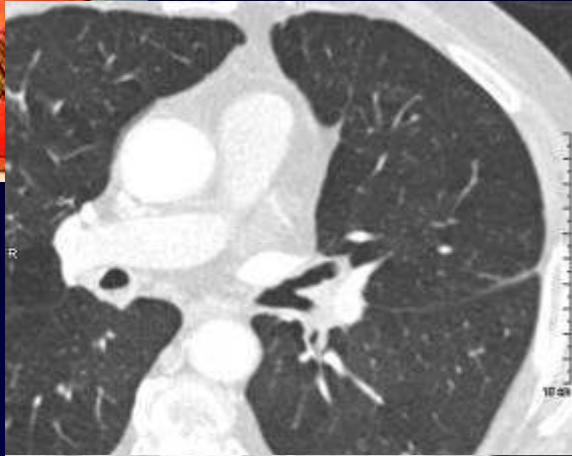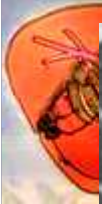7.10.06

04



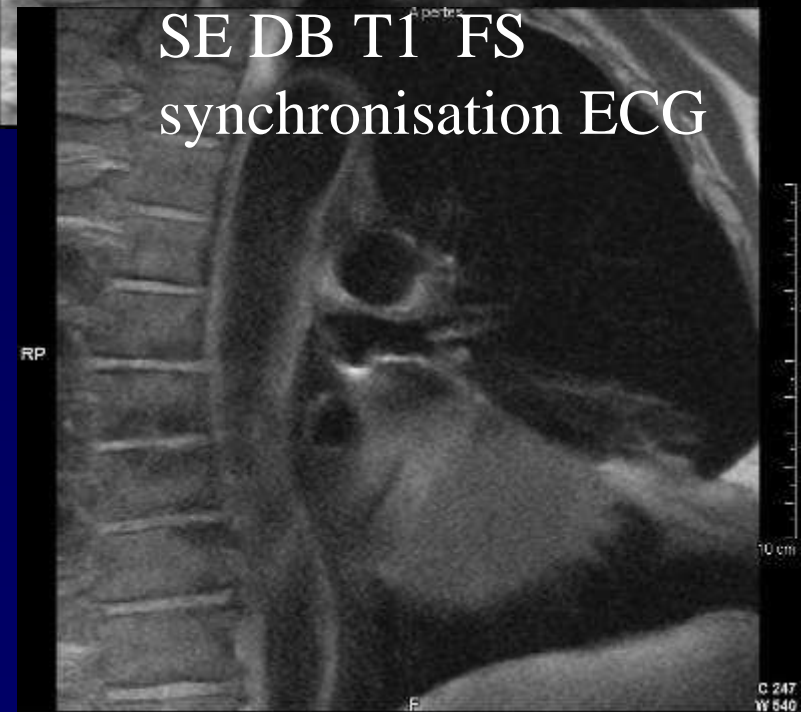
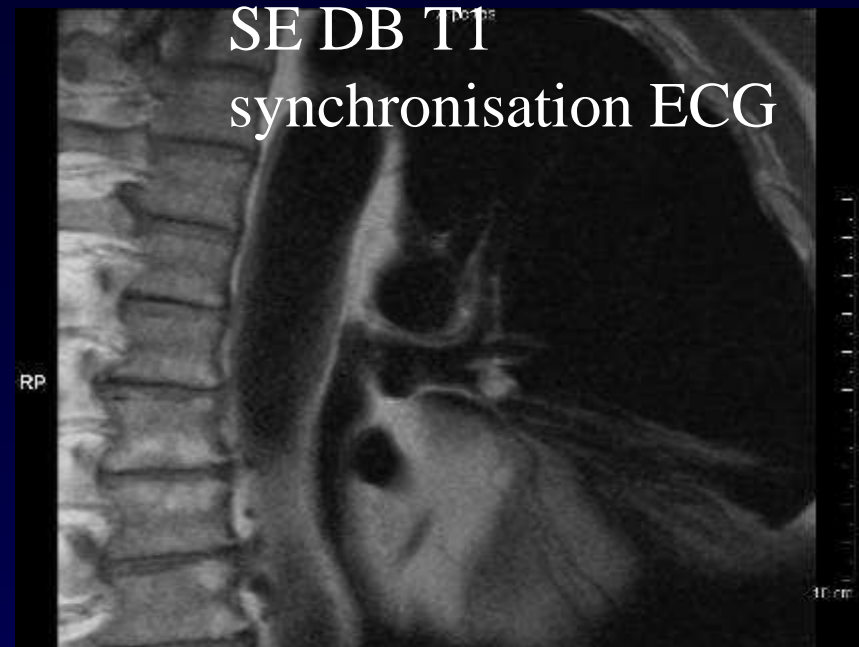
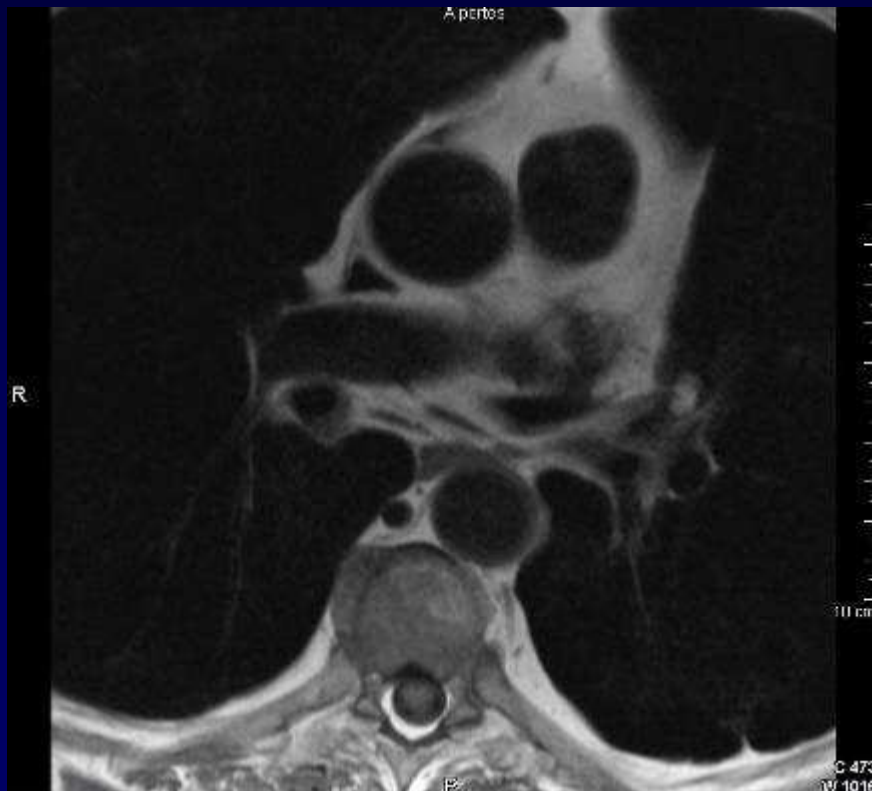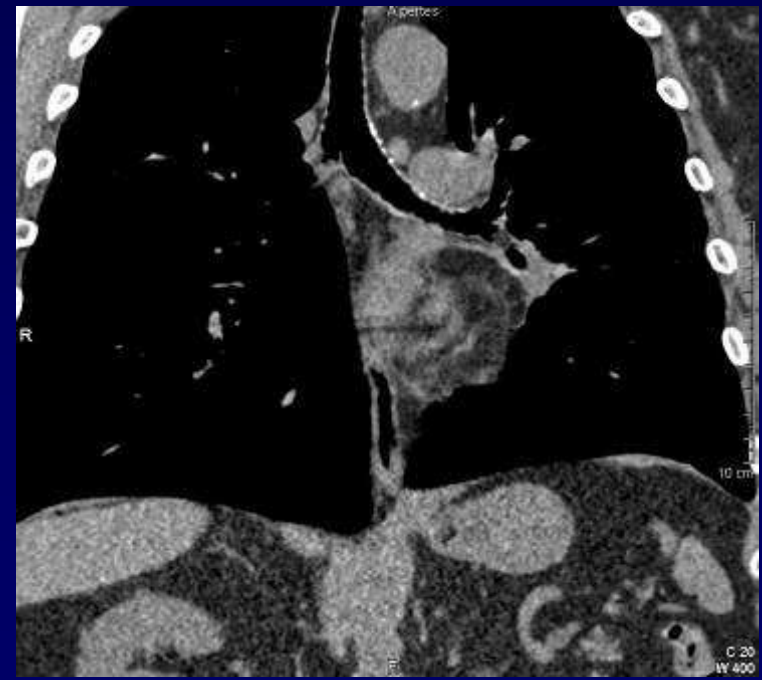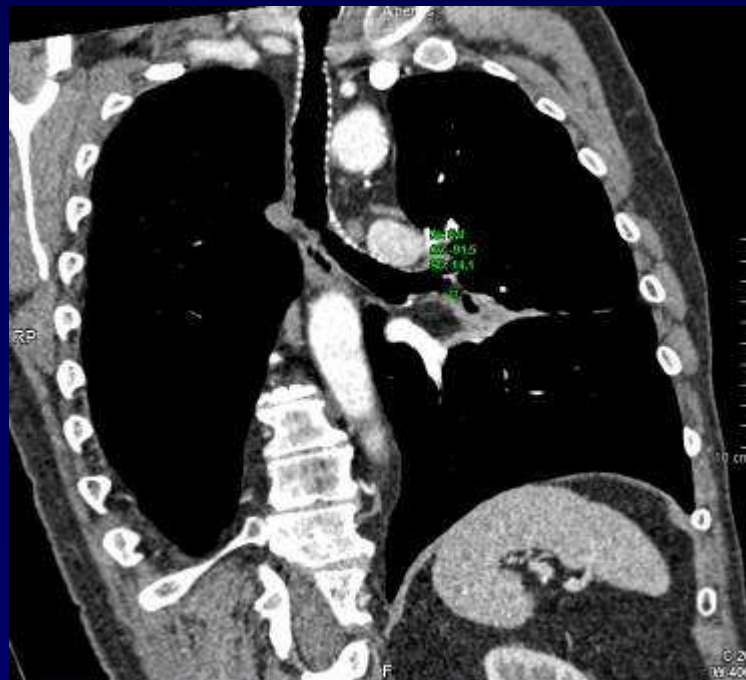
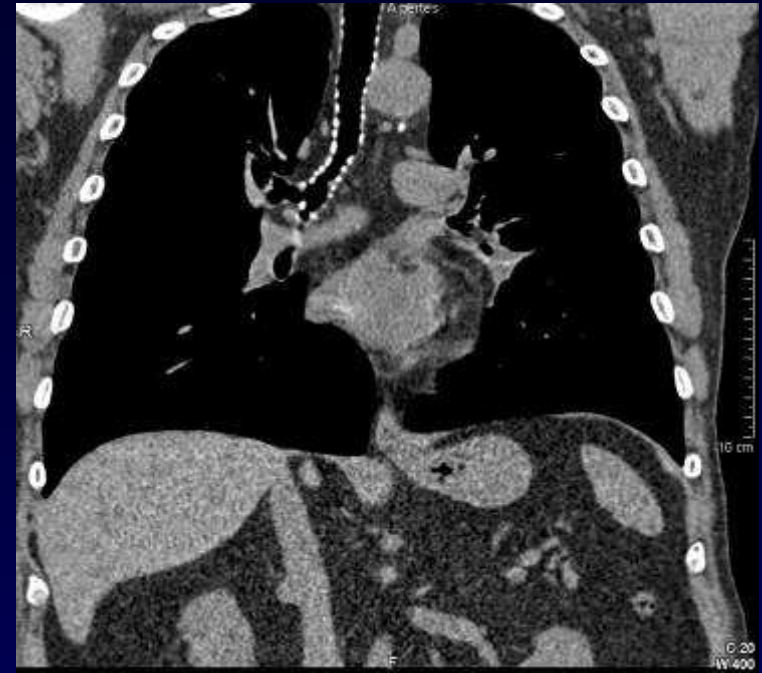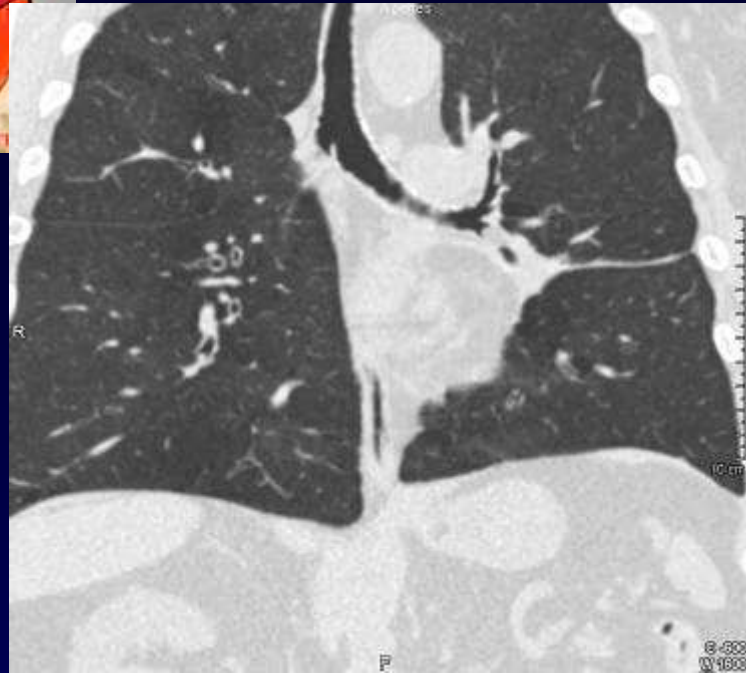





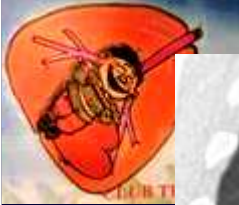
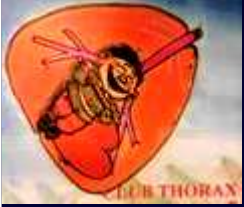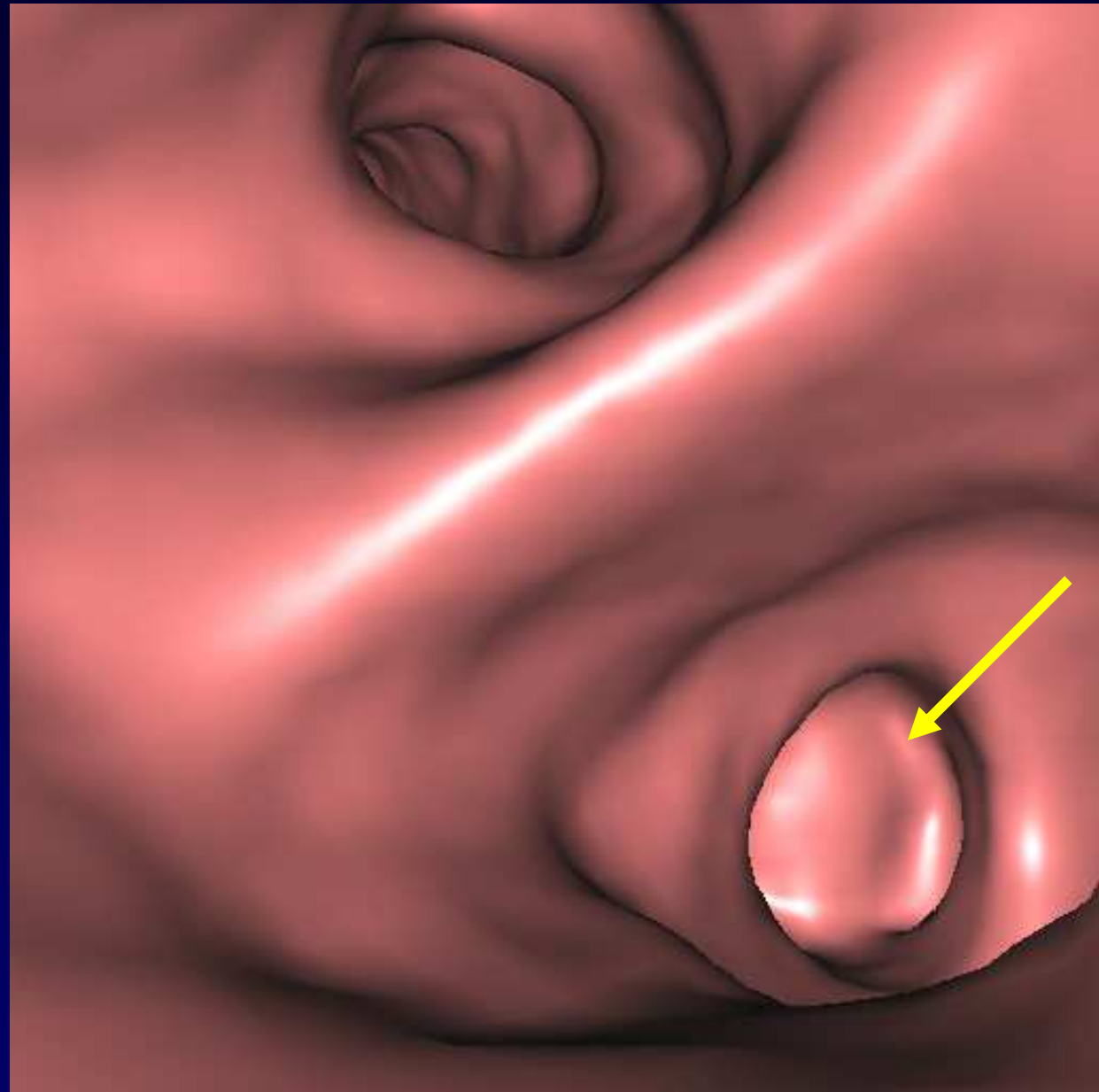
SE DB T1 synchronisation ECG







Diagnostic ?





Diagnostic

- La fibroscopie bronchique confirme l'obstruction de la bronche linguale par une tumeur ronde à parois lisses et mobiles avec la respiration
- Biopsie: **Lipome**

Codage : Poumon – Tumoral bénin